

Neoplasms of the Appendix

Current Treatment Guidelines

Suven Shankar, ^aMBBS^a, Panayotis Ledakis, MD^b,
Hatem El Halabi, MD^a, Vadim Gushchin, MD^a,
Armando Sardi, MD^{a,*}

KEYWORDS

- Appendix cancer • Disseminated peritoneal adenomucinosis (DPAM)
- Peritoneal mucinous carcinoma appendix (PMCA) • Cytoreductive surgery (CRS)
- Hyperthermic intraperitoneal chemotherapy (HIPEC) • Peritoneal carcinomatosis

KEY POINTS

- Appendix tumors are rare and biologically diverse.
- Early referral after appendectomy results in improved outcomes.
- When confined to the abdominal cavity, peritoneal carcinomatosis from appendiceal origin is effectively treated with cytoreductive surgery (CRS) and hyperthermic intraperitoneal chemotherapy (HIPEC).
- Lymph node involvement is associated with poor prognosis.
- Patients with peritoneal carcinomatosis from appendiceal tumors should be referred and treated at a specialized center.

INTRODUCTION

Appendiceal cancers are found in less than 1% of appendectomy specimens.¹ A population-based study from the Surveillance, Epidemiology and End Results program (SEER), from 1973 to 1998, reported the incidence of cancer of the appendix was 0.12 cases per 100,000 people per year and that the most common histology was mucinous adenocarcinoma.²

Neoplasms of the appendix are not often suspected before surgery and are found either intraoperatively or on pathologic examination. The increasing awareness of the disease and its pathophysiology and presentation has sparked an increased interest in the surgical and medical oncology fields with respect to the treatment of diseases

Disclosure: None.

Conflict of Interest: None.

^a Department of Surgical Oncology, Institute for Cancer Care, Mercy Medical Center, 227 Saint Paul Place, Baltimore, MD 21202, USA; ^b Department of Medical Oncology and Hematology, Institute for Cancer Care, Mercy Medical Center, 227 Saint Paul Place, Baltimore, MD 21202, USA

* Corresponding author.

E-mail address: asardi@mdmercy.com

Hematol Oncol Clin N Am 26 (2012) 1261–1290

<http://dx.doi.org/10.1016/j.hoc.2012.08.010>

hemonc.theclinics.com

0889-8588/12/\$ – see front matter © 2012 Elsevier Inc. All rights reserved.

with peritoneal dissemination. The first reference to carcinoma of the appendix was a case reported by Merling in 1838.³ In 1903 Elting reported a review and case series from 1838 to 1903. Forty-three cases of neoplasms of the appendix were reported of which only 23 were true carcinoma of the appendix. Awareness of neoplasms of the appendix is increasing. They were previously diagnosed as mucinous neoplasms of the ovary. Recent immunohistochemical, molecular, and genetic evidence support an origin in the appendix in most cases with secondary involvement of the peritoneum and/or ovaries. More recently, the classification of the appendiceal carcinomas has been separated from the colorectal tumors in the seventh edition of the American Joint Committee on Cancer *Cancer Staging Manual*.⁴

The appendix first appears at the eighth week of gestation as an out-pouching of the cecum and gradually rotates to a more medial location. Its length varies from 2 cm to 15 cm and is located at the convergence of the taeniae along inferior aspect of the cecum. The tip of the appendix is most commonly retrocecal, but it is pelvic in 30% and retroperitoneal in 7% of the population.⁵ The lymphatic drainage is into the anterior ileocolic lymph nodes and histologic examination shows goblet cells that are scattered throughout the mucosa.

An analysis from the SEER 1973 to 2004⁶ database of appendiceal cancers (n = 2791) showed that adenocarcinoma accounted for 65.4% of appendiceal cancers, followed by neuroendocrine neoplasms (0.1%–0.2% over 30 years). The incidence of neuroendocrine neoplasms seemed stable whereas that of adenocarcinoma increased 2.6-fold during that time. The overall 5-year survival of appendiceal adenocarcinomas was reported in the SEER database as 46.2%. The reported 5-year survival for subgroups was adenocarcinoma 47.9%, mucinous adenocarcinoma 47.7%, mucinous cystadenocarcinoma 59.0%, signet ring cell carcinoma 20.3%, and lymphomas were 1.7%.⁶

PATHOLOGY

Appendiceal tumors can be broadly classified as epithelial and nonepithelial tumors.⁷

Epithelial Tumors

There are many existing classifications of epithelial appendiceal neoplasms and this reflects the lack of consensus among the pathologists. The limitations of all classification systems are well recognized and even a benign-appearing tumor may exhibit aggressive clinical course.

In 1940, Woodruff and McDonald classified cystic mucinous tumors of the appendix as mucocoeles and cystadenocarcinoma grade 1 but by the 1960s to 1970s they were reclassified as mucinous cystadenomas or villous adenomas of the appendix. Higa and colleagues⁸ in 1973 classified appendiceal mucinous tumors as cystadenocarcinomas if associated with pseudomyxoma peritonei and cystadenomas if not. Over the past decades there has been controversy among pathologists regarding the classification of some appendiceal tumors due to lack of consensus on the invasive potential of the appendiceal epithelial cells. Some pathologists require destructive invasion of the appendix with infiltrating glands to make the diagnosis of adenocarcinoma and others require the presence of a broad front with neoplastic epithelium directly abutting the hyalinized cyst wall thinning out the muscularis mucosae.⁷

In 1995, Carr and colleagues⁹ reviewed 184 tumors at the Armed Forces Institute of Pathology and proposed the following classification:

1. Adenoma: dysplastic epithelium with mucin dissecting into wall with intact muscularis mucosae

2. Mucinous tumors of uncertain malignant potential: well-differentiated mucinous epithelium without invasion or with mucin in the wall or outside the appendix with loss of muscularis mucosae
3. Adenocarcinoma: invasive neoplastic cells beyond muscularis mucosae

In 2003 Misdraji and colleagues¹⁰ classified them as low-grade mucinous neoplasms and mucinous adenocarcinoma.

Pai and Longacre¹¹ in 2005 also proposed a classification:

1. Adenoma: mild-to-moderate atypia, mitosis, no stromal invasion, perforation with mucin
2. Mucinous tumor of uncertain potential: adenoma with positive margin, mucin present within the wall
3. Mucinous tumor–low malignant potential: adenoma with neoplastic cells in peritoneum
4. Adenocarcinoma: invasive mucinous tumor

In 1995, Ronnett and colleagues¹² analyzed the clinicopathologic features of 109 cases of multifocal peritoneal mucinous tumors and classified these as

1. Diffuse peritoneal adenomucinosis (DPAM): mucin with fibrosis and scant simple to focally proliferative mucinous epithelium with minimal cytologic atypia and mitotic figures. The primary appendiceal tumor was an adenoma in all these cases.
2. Peritoneal mucinous carcinoma (PMCA): the primary tumor is appendiceal adenocarcinoma with peritoneal tumors having more proliferative epithelium with signet ring cells and marked cytologic atypia.

There were 14 of 109 cases that were classified as PMCA–I (intermediate) because they showed features of DPAM with carcinoma in the peritoneal lesions, whether or not the primary site demonstrated carcinoma. In a follow-up study, Ronnett¹² clarified that PMCA–I should be included into the PMCA group because they behaved similarly.

The authors' group uses the modified Ronnett classification for peritoneal dissemination of appendiceal neoplasms.¹² Its advantage is that it approximately divides the tumors into less-aggressive DPAM and more-aggressive PMCA, the latter having a potential to develop nodal, liver, and other metastases.

Every team specializing in treatment of appendiceal malignancies should establish a clear communication with a pathologist to have a common language when classifying the appendix tumors. Also, a critical review of the oncological outcomes should be conducted periodically to realign the pathologic classification used and the clinical practice. Further efforts should be undertaken by the collaboration of all centers treating these conditions to try to standardize the pathology of appendiceal neoplasms.

Nonepithelial Tumors

1. Endocrine tumors
 - a. Classic appendiceal endocrine tumors
 - b. Goblet cell carcinomas
2. Lymphoma
3. Sarcoma

Endocrine tumors are classified according to the World Health Organization and TNM classifications.^{13,14}

WHO classification

- a. Well-differentiated endocrine tumor (benign behavior and uncertain behavior)
- b. Well-differentiated endocrine carcinoma, low grade, malignant
- c. Mixed exocrine-endocrine, malignant, goblet cell carcinoid (GCC)

A TNM classification and grading scheme was proposed by the European Neuroendocrine Tumor Society in 2007 (**Table 1**).

GCC tumors of appendix are rare endocrine tumors that have various names, such as adenocarcinoid, mucinous carcinoid, crypt cell carcinoma, and mucin-producing neuroendocrine tumor, but first coined, *goblet cell carcinoid*, in 1974 by Subbuswamy and colleagues.¹⁵ Current understanding of GCC's origin states that it is an amphicrine tumor, which originates from a single undifferentiated pluripotent intestinal epithelial crypt base progenitor stem cell that has dual neuroendocrine and mucinous differentiation. The natural history of these tumors is intermediate between carcinoids and classical adenocarcinomas of the appendix¹⁶; hence, a proposed name is mucin-producing neuroendocrine tumor (or carcinoma) of the appendix. Unlike adenocarcinomas, K-ras and β -catenin expression is absent in these tumors. These tumors show allelic loss of chromosomes 11q, 16q, and 18q, similar to ileal carcinoids.

Classification

Group A: typical low-grade GCC

Group B: adenocarcinoma ex GCC with signet ring cell type

Group C: adenocarcinomas ex GCC, poorly differentiated

CLINICAL PRESENTATION OF NONEPITHELIAL AND EPITHELIAL NEOPLASMS OF THE APPENDIX

Carcinoids

Carcinoids are most commonly located at the tip of the appendix and they present most of the time with appendicitis. They are divided into 2 types. The insular type resembles enterochromaffin cell and produces serotonin. Lymph node and liver metastasis are rare. The tubular variant of carcinoid arises from the L-cell, which produces enteroglucagons and peptide YY. Immunohistochemistry can distinguish an adenocarcinoma from a tubular carcinoid because the latter is positive for chromogranin and/or synaptophysin. Tumors less than or equal to 1 cm require only an appendectomy. If 1 cm to 2 cm in size without involvement of the base of appendix, they are managed with appendectomy and the question of adding a right hemicolectomy depends on grade, mitotic activity, invasion of mesoappendix, or lymphovascular invasion. These patients should be discussed at a multidisciplinary conference. Tumors 2 cm or larger are at risk for lymph node or distant metastasis and a right hemicolectomy is indicated. Also, for tumors with invasion into the

Grade	Mitotic Count (10/HPF) ^a	Ki -67 Index (%) ^b
G1	<2	<2%
G2	2–20	3%–20%
G3	>20	>20%

^a 10 high power field (HPF) = 2 mm², at least 40 fields (at 40 × magnification) evaluated in areas of highest mitotic density.

^b MIB1 antibody; % of 2000 tumor cells in areas of highest nuclear labeling.

mesoappendix, lymphovascular invasion, or increased mitotic activity (Ki index >3%), a right hemicolectomy should be considered.¹⁷

Goblet Cell Carcinoids

The most common presentation is appendicitis but could also be a bowel obstruction, intussusception, gastrointestinal bleeding, and chronic lower abdominal pain. More than 50% of patients present with metastatic disease and frequently an appendiceal primary is not considered. This is more common in women, who have ovarian metastasis and are misdiagnosed as having ovarian primary. None of the patients presents with carcinoid syndrome, and urinary 5-hydroxyindoleacetic acid levels and other neuroendocrine markers are usually within normal limits. The clinical outcome of GCC is more favorable than stage-matched adenocarcinoma of the appendix. The most common route of metastasis is transcoelomic but metastasis to lymph nodes, ribs, and vertebra are also reported. Stage and grade of the tumor are important prognostic factors. High mitotic activity, high Ki index greater than 3%, nodal involvement, angioinvasion, and increased mucin production indicate aggressive behavior.¹⁶

Epithelial Tumors

Patterns of presentation vary widely, which adds to the inability of initial care providers to diagnose correctly the cause of appendiceal neoplasms. The tumors present as an incidental finding in the appendectomy specimen, for appendicitis, as a pelvic mass or as peritoneal carcinomatosis with or without ascites. Appendicitis is a common presentation in men and woman combined¹⁸ but peritoneal dissemination of mucinous appendiceal neoplasm is an important initial presentation. Patients also present to primary care physicians with abdominal distension, increasing abdominal girth, fatigue, weight gain, shortness of breath, and early satiety. Women are usually referred to a gynecologist for possible ovarian cancer. A high percentage of patients are referred to general surgeons after debulking gynecologic surgery for pelvic masses presumed of ovarian origin. Umbilical, inguinal, and incisional hernias filled with mucin, discovered at the time of hernia surgery, is another mode of presentation.

When the mucin extrudes through the appendicular wall due to increased intraluminal pressure, the mucin-producing tumor cells are released into the free peritoneal cavity (**Fig. 1**). The flow of mucin follows that of peritoneal fluid and circulates in a clockwise direction from the right paracolic sulcus, right subdiaphragmatic area, retrohepatic vena cava, left diaphragm, splenic hilum, and ligament of Treitz. The

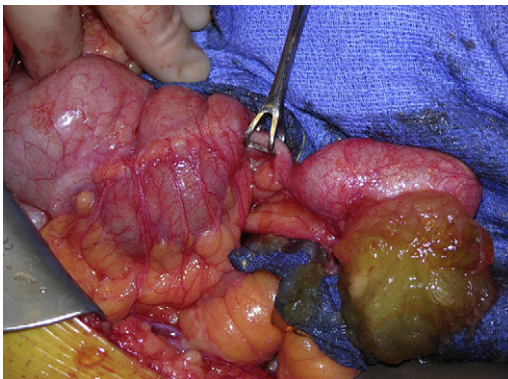


Fig. 1. Appendiceal neoplasm with mucin extrusion.

falciform ligament directs flow to the pelvis, the cul de sac, left paracolic sulcus, and ovaries. The small bowel due to peristalsis is generally initially not involved with the mucinous implants.¹⁸

DIAGNOSIS

The goals of the work-up include staging of the appendiceal tumor, characterizing the biologic behavior by its histology, clinical history, physical examination, and radiologic studies and deciding if surgery should be a part of the treatment plan. The authors recommend summarizing the final work-up and pretreatment diagnosis by a team familiar with treatment of appendiceal neoplasms and patients with peritoneal carcinomatosis. The reason for this recommendation is that patients could be denied surgical treatment and a chance for long-term survival based on widespread belief that peritoneal carcinomatosis is a contraindication for aggressive surgery. Only an experienced cytoreduction surgeon could determine if complete removal of all visible tumor is possible or if debulking surgery for palliation could help improve the quality of life (QOL) in patients with large accumulation of mucin. As discussed previously, the clinical presentation should be a clue to the physician about a potential appendiceal neoplasm. The physical examination of such patients should also include a digital rectal and pelvic examination to assess for masses in the pelvis and the mobility of these structures to the surrounding anatomy. It is confirmed by preoperative imaging studies, intraoperative findings, or postoperative pathology results. Delay in diagnosis is a common problem due to lack of understanding of the pathophysiology of this condition. The authors' group presented data that the time from diagnosis to treatment with CRS and HIPEC of more than 6 months correlated with worse outcome.

Preoperative Studies

CT

Most patients have a CT scan of the abdomen and pelvis before being referred to a peritoneal surface malignancy program. Findings suggestive of an appendiceal neoplasm are appendiceal dilation or mass and gross ascites with a mucinous component. The mucin maybe seen distributed as discussed previously or in hernia sacs when present. There is nodularity of the lining of the diaphragm and potential indentations on the surface of the liver from the solid component of mucin. The mesentery of the small bowel could be foreshortened from the fibrotic reaction of the tumor in the mesentery leading to a mushroom-shaped image on CT scan (**Fig. 2**). Rarely, hydroureter (**Fig. 3**) is seen when tumor involves the vesicoureteral junction, which may have compromised renal function **Fig. 4** shows extensive involvement of all areas of the peritoneal cavity. PET scan have not shown promise in the case of DPAM or PMCA.¹⁹ The use of MRI is attractive due to reduced radiation exposure but its use should be determined based on the expertise of a radiologist to read abdominal MRI.

Tumor markers

Carcinoembryonic antigen (CEA), CA19-9, and CA-125 are potential tumor markers in epithelial appendiceal neoplasms. One or any combination of them can be elevated in 60% of patients. A preoperative level is routinely done. Their use is primarily for follow-up and as a response to therapy. After CRS and HIPEC, they are helpful in following a patient's clinical status and are indicative of recurrence. The elevation can precede the CT findings by several months. None of them is specific to either DPAM or PMCA. Multiple abnormal tumor markers were not useful as an exclusion criterion for

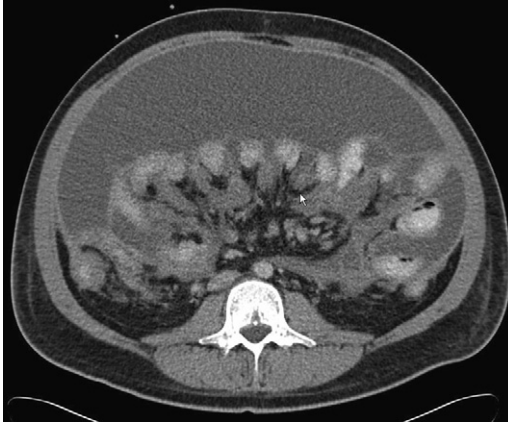


Fig. 2. Foreshortened mesentery on preoperative CT scan.

patients undergoing CRS. The 3-year survival rates in patients with elevated versus nonelevated CA-125 levels were 83% versus 52% ($P = .003$); hence, an elevation in CA-125 is an important indicator of survival in these patients.²⁰

Preoperative Evaluation for Cytoreductive Surgery and Hyperthermic Intraperitoneal Chemotherapy

A thorough history and physical examination is important. Laboratory studies, including complete blood cell count and complete metabolic panel with tumor markers, CEA, cancer antigen (CA) 19-9, and CA-125, are obtained. A CT scan of the chest abdomen and pelvis with oral and intravenous (IV) contrast is important in assessment. Preoperative clearance studies in the form of ECG or chest radiograph (if no CT scan) are obtained. Cardiac stress test is indicated when patients are older than 65 years or have

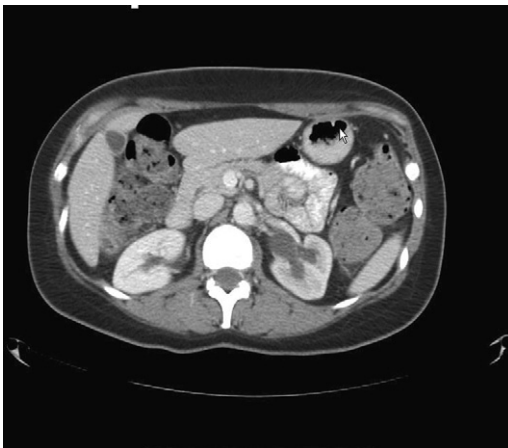

Fig. 3. Left-sided hydronephrosis secondary to tumor at vesicoureteral junction.

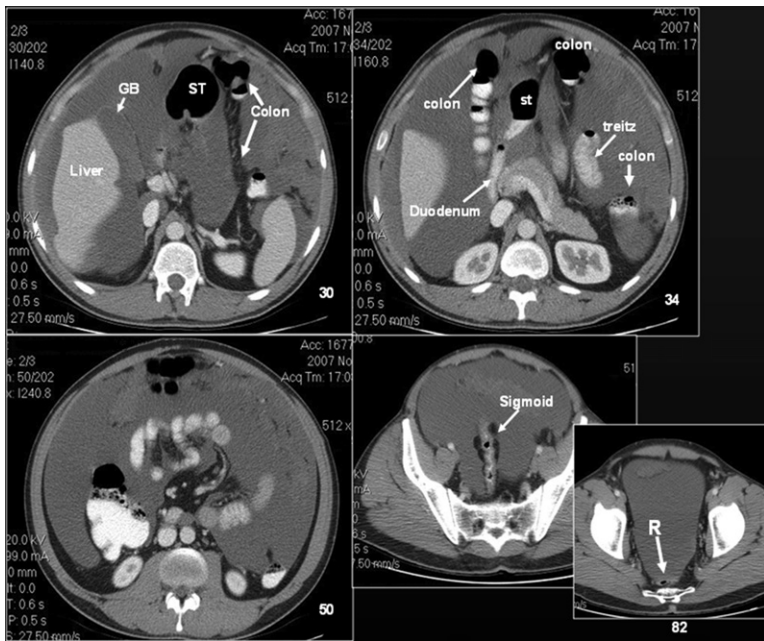


Fig. 4. Depiction of extensive involvement of tumor in all areas of the peritoneal cavity. GB, gallbladder; R, rectum; ST, stomach.

a positive cardiac history. The patients are also required to have a colonoscopy to assess for any polyps or masses. Split renal function studies are indicated only in a rare situation where a nephrectomy maybe considered necessary.

Contraindications to CRS/HIPEC

Absolute

1. Extension outside the peritoneal cavity
2. Biliary obstruction
3. Multiple small bowel obstructions

Relative

1. Poor functional status of patient
2. Cardiac contraindication
3. Foreshortened mesentery that would result in postoperative short bowel syndrome. Although the CT scan can suggest it, it is not always a reliable sign.

Parenchymal involvement of the liver, which is rare in appendiceal neoplasms, is not a contraindication to CRS and HIPEC but should be amenable to a complete resection.

SURGICAL TECHNIQUE AND POSTOPERATIVE CARE

Laparoscopy can be utilised to access the extent of small bowel involvement, but in patients with extensive disease in the omentum and previous surgeries, it is difficult

to evaluate completely the extent of small bowel involvement. It is imperative to place all laparoscopic ports in the midline in an effort to reduce port site recurrences that could complicate further surgery. The authors' group has demonstrated a postsite recurrence of 34% of port sites resected. The extent of small bowel resection determines the QOL after cytoreduction. Every effort should be made to minimize bowel resection even if it requires multiple anastomosis or wedge resections to accomplish that goal.

Under general anesthesia, a midline xiphopubic incision is used to gain access to the abdominal cavity. Tumor burden is calculated using the peritoneal cancer index (PCI), as reported by Sugarbaker (Fig. 5).²⁰

Lesion size score is applied to each of the 9 abdominopelvic regions, the jejunum, and the ileum. Summation of the lesion size score gives the PCI (range = 1–39).¹⁸ Surgical resection of the primary tumor is done followed by peritonectomy procedures originally described by Sugarbaker.²⁰ The extent of surgery is determined by the size and location of the tumor. The objective is to remove all visible tumor (complete cytoreduction). Complete resection is defined as completeness of cytoreduction score, CC-0 or CC-1 (Box 1).

Findings at surgery could be consistent with appendiceal mass, mucin in the abdomen, bowel obstruction from mucinous component, foreshortened mesentery, peritoneal implants, diaphragmatic implants, masses, or nodules at previous laparoscopic port sites.

Peritonectomy procedures are done as needed to achieve a good cytoreduction and may include anterior abdominal wall peritonectomy, greater omentectomy and splenectomy; left and right upper quadrant peritonectomies with stripping of the respective hemidiaphragms, which requires the placement of chest tubes; lesser omentectomy with cholecystectomy and stripping of the omental bursa and porta hepatis; or pelvic peritonectomy with total abdominal hysterectomy and bilateral salpingo-oophorectomy with/without anterior resection of the rectum. Visceral peritonectomy and resection is frequently needed to accomplish this goal. Final assessment of cytoreduction is recorded based on the CC score (see Box 1).

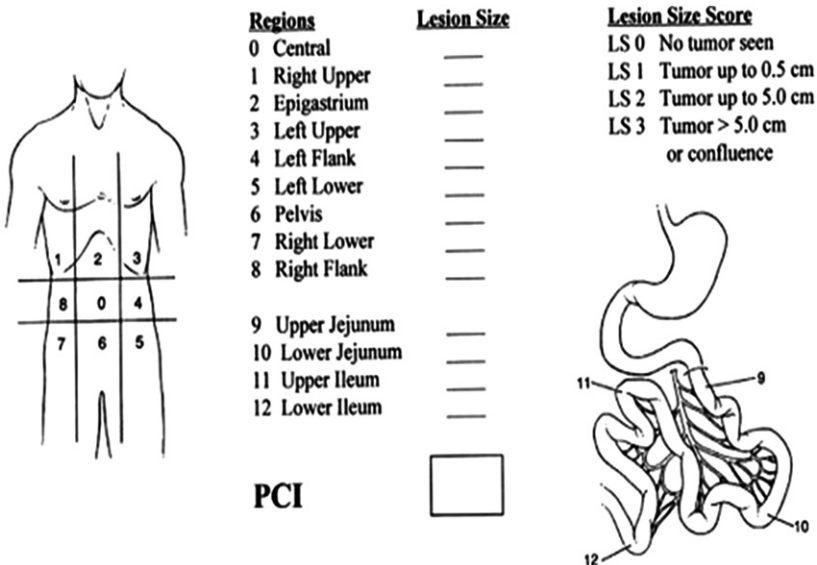


Fig. 5. PCI chart.

Box 1**Estimating the CC score with respect to residual tumor size after cytoreduction**

CC-0 = No visible tumor

CC-1 = 0–0.25 cm

CC-2 = 0.25–2.5 cm

CC-3 = >2.5 cm

After the cytoreduction and before any anastomosis is made, HIPEC is performed intraoperatively with mitomycin C for 90 minutes at a total dose of 40 mg (30 mg given initially and 10 mg added after half an hour of perfusion) using a closed technique. The outflow temperature is maintained at 41°C to 42°C. Urine output is maintained (250–400 mL/h) by using crystalloids and albumin to prevent renal toxicity. During the perfusion the patient is shaken manually and the operating table is positioned in different directions every 15 minutes. On completion of perfusion, the abdomen is opened and gastrointestinal reconstruction is done as appropriate.

Patients are transferred to an ICU where hemodynamic parameters and fluid status are carefully monitored. The authors' practice is to place chest tubes bilaterally immediately postoperatively when diaphragmatic peritonectomy is performed. The Jackson-Pratt drains that are placed in the Morison pouch, pelvis, and near the tail of pancreas are also monitored. Patients are subsequently transferred to the surgical floor when stable. Usually the following morning, physical therapy is started on postoperative day 1 and early mobilization is encouraged. Deep vein thrombosis prophylaxis is implemented during and after using compression stockings, low-molecular-weight heparin, and early mobilization. Patients are discharged from hospital when clinically stable. Patients from out of town are requested to stay in town to make sure they can maintain good hydration and nutrition. It is important to be proactive because patients become dehydrated and consult late, leading to increased rate of readmissions. Baseline clinical assessment with complete physical examination; CT scan or MRI of chest, abdomen, and pelvis; and tumor markers is done at 2 months postoperatively, then every 6 months for the first 5 years, and then yearly until year 10.

Important Technical Considerations***Open or closed HIPEC***

The open and closed techniques for intraperitoneal hyperthermic chemotherapy have been used.²¹ To date, no conclusive evidence exists that one is superior to another.²²

Initial entrance into abdominal cavity

Most patients present to the authors with multiple previous surgeries and with advanced disease. Entrance into the abdomen should be performed carefully because frequently adhesions to the small bowel can lead to multiple enterotomies and consequently increased small bowel resections and increased complications. If possible, the abdominal cavity is entered high in the epigastric region where the liver or stomach can be found easily with less incidence of bowel adhesions.

Approach to the porta hepaticus during CRS

CRS and HIPEC have become important options for patients with peritoneal carcinomatosis. The CC determines survival. Frequently, the porta hepaticus and the lesser sac are massively involved by tumor (**Fig. 6**). Encasement of portal triad, lesser omentum, retrohepatic vena cava, duodenum, and stomach is frequently seen. The proximity to major portal structures and retrohepatic vena cava makes this dissection

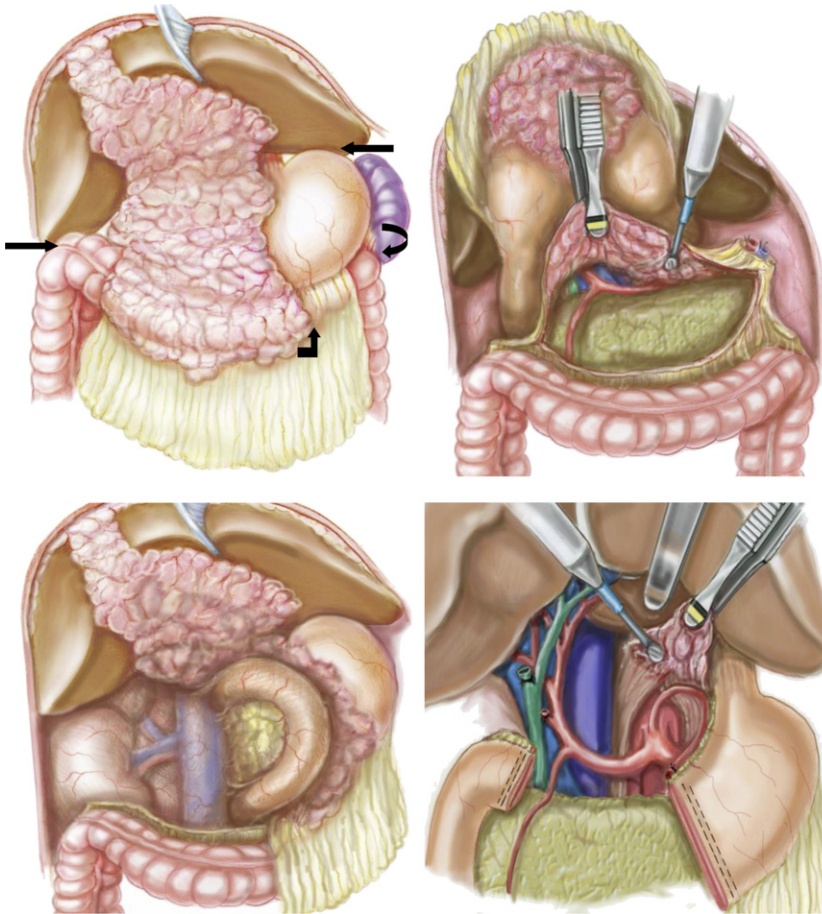


Fig. 6. (Top left) Extensive tumor burden over porta hepaticus; black arrows show routes of access to porta hepaticus. (Top right) Mobilization of tumor over pancreas to expose common hepatic artery. (Bottom left) Kocherization of duodenum. (Bottom right) Dissection of retrohepatic IVC and crus of diaphragm.

challenging. In the authors' experience, this is the area where meticulous surgical technique and expertise are necessary to obtain complete removal of all tumor. Some specific technical considerations are important to assure that all tumor is safely removed. These are

- Determining the extent of resection of other areas of the abdomen to assure the level of cytoreduction that can be accomplished
- Determining the extent of bowel resection needed to evaluate if a partial gastrectomy will significantly worsen QOL
- Performing right and left diaphragmatic peritonectomies and mobilizing all ligaments of the liver to obtain adequate liver mobility with the dissection of the round ligament at the end
- Completing mobilization of the greater curvature of stomach to evaluate the extent of involvement of the lesser sac

- Performing cholecystectomy and peritonectomy over the infrahepatic vena cava to gain access to the foramen of Winslow and portal triad. Peritonectomy at this level needs to be extended as far as possible to the retrohepatic vena cava and segment 1 of the liver, including the posterior aspect of the portal triad. This maneuver makes the dissection from the lesser sac easier.
- If the portal triad is not accessible anteriorly, as is frequently the case, it should be approached through the gastrocolic space (see **Fig. 6**). Performing the peritonectomy over the pancreas, where there is frequently large tumor bulk, facilitates the exposure to the celiac trunk and hepatic artery. Once the hepatic artery is identified and protected, the dissection can be carried anteriorly to the portal triad (**Fig. 7**) by transecting the tumor and separating stomach and duodenum from the porta hepaticus (see **Fig. 6**). The dissection is continued along the anterior aspect of the portal triad toward the base of the round ligament.
- Separating the lesser omentum by incising the peritoneum close to the liver down to the anterior portion of segment 1. An accessory left hepatic artery from the left gastric artery if present can be ligated. Extend the dissection over segment 1

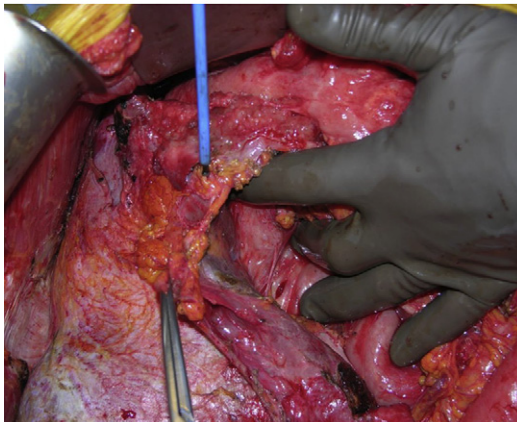
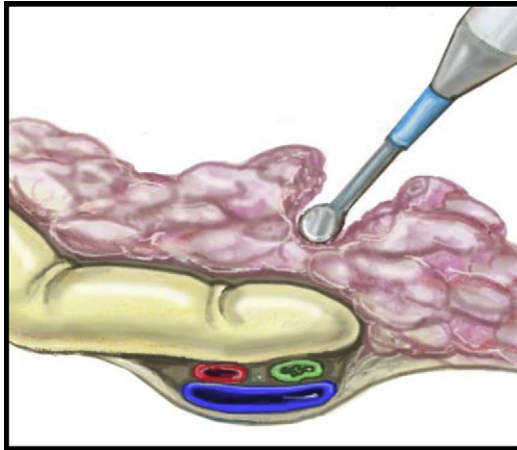


Fig. 7. Anterior approach to portal structures.

toward the foramen of Winslow to meet the previous dissection from the infrahepatic vena cava.

- Starting the dissection of the retrohepatic vena cava superiorly at the level of the esophagogastric junction and right crux of the diaphragm. By elevating this peritoneum, the left hepatic vein and inferior vena cava (IVC) can be approached safely. A Heywood-Smith clamp facilitates the traction and the peritoneum over the IVC and it can be dissected anteriorly at its junction to the liver. Dissection is extended inferiorly to meet the previous dissection from the foramen of Winslow. Once the portal area has been cleared (**Fig. 8**), the authors proceed to clear the round ligament. In this area, the tumor is frequently deeply imbedded into the fissure.
- To obtain complete cytoreduction in these cases, a partial gastrectomy is frequently required. If this is the case, the transection of the antrum can be done first to facilitate the exposure of the porta hepaticus, but this should only be done once it is clear that the portal triad can be cleared and the first or second portion of duodenum is free of tumor for appropriate closure.

This meticulous surgical technique may allow complete cytoreduction in patients with high volume disease who otherwise would not be considered surgical candidates. The authors prefer low current electrocautery for dissection of the porta hepaticus,²³⁻³³ allowing good hemostasis while minimizing the possibility of injury to the portal structures.

Bowel Resection and Anastomoses

It has been suggested that approximately 150 cm of small bowel should be left behind and 200 cm if a total colectomy is performed to avoid a short gut syndrome. This may require multiple anastomoses. All anastomosis are performed after the completion of the hyperthermic chemotherapy. The only exception is the esophageal anastomosis, due to the difficulty in performing the esophagojejunostomy when post-HIPEC edema is present. There are multiple ways to perform an anastomosis. The authors' preference is as follows.

Anastomosis of the stomach to small bowel is performed with an interrupted hand sewn single layer technique using 3.0 silk (Billroth II type end-to-side retrocolic gastrojejunostomy). The stomach is sutured to the transverse mesocolon to keep the anastomosis in the infracolic position and avoid constriction of the bowel loop. If resection of the lesser omentum without gastrectomy compromised the vagus nerve,

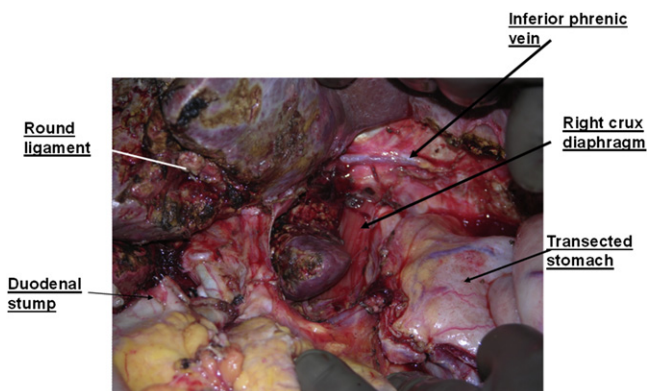


Fig. 8. Completed portal dissection.

an interrupted single layer pyloroplasty using 3.0 silk sutures (Heineke-Mikulicz type) is performed. For total gastrectomy, an end to side esophagojejunostomy (roux-en-Y) is done using a 28-mm EEA stapler. A total gastrectomy is rarely required even in patients with bulky disease.

The small bowel to small bowel, small bowel to colon, and colon to colon anastomoses are done with stapled side-to-side functional anastomosis using a linear cutter GIA-55, 3.2 mm, and a TA-55. The crossover of the staple lines is reinforced by 3.0 silk sutures.

Colorectal anastomosis is done with EEA 31-mm, 4.2-mm stapler. After the anastomosis is performed, the anastomotic rings are inspected and the anastomosis tested for leaks by insufflating air into the rectum while the pelvis is filled with normal saline. Protective ileostomies are not routinely performed. Commonly the rectal stump is at the level of the seminal vesicles or midvagina.

Occasionally, the authors perform a protective ileostomy in cases of extensive dissection of the distal rectum in patients with previous low anterior resections.

PROGNOSTICS INDICATORS OF TREATMENT OF APPENDICEAL NEOPLASM USING CRS AND HIPEC

Completeness of Cytoreduction

This is a major quantitative prognostic indicator for mucinous appendiceal neoplasms that is performed after CRS has been completed (**Fig. 9**). A complete cytoreduction is defined as CC-0 or CC-1.

The optimal cytoreduction of 2.5 mm has been adopted because it is the size of tumor that correlates with the level of penetration of the different agents used intraperitoneal hyperthermic chemotherapy.¹⁸ CC score is an important prognostic indicator discussed by different investigators.^{34–36} It is the only prognostic variable that is affected by the surgeon. It is important that every effort be made to accomplish a complete cytoreduction regardless the time required for it.

Omohwo and colleagues³⁷ have reported 60% overall 3-year survival for patients with high-grade appendiceal neoplasm. Survival by CC was 78% for patients with a low CC score (0–1) and 28% in patients with a high CC score (2–3; $P = .01$). Survival analysis by tumor histology was 80% for patients with low-grade tumors and 52% for patients with high-grade tumors ($P = .024$).

Histopathology

The survival of patients treated with CRS and HIPEC is affected significantly by the histopathology and patients with DPAM have better long-term survival than those with PMCA (see **Fig. 10**). The 5-year survival range for PMCA ranges 40% to 45%.¹⁹

Peritoneal Cancer Index

The PCI is determined at the time of surgical exploration of the abdomen/pelvis.²¹ Higher levels of PCI have been associated with lower survival. This significance is more notable in patients with PMCA. Even though PCI has prognostic significance, it should not be considered an exclusion criteria.

El Halabi and colleagues³⁵ showed that with PMCA patients who had complete cytoreduction, the 5-year overall survival with PCI greater than 20 was 45% and PCI less than 20 was 66%. Patients who underwent a complete cytoreduction, excluding PCI data, had a 5-year overall survival of 40%.³⁵ Sugarbaker¹⁸ (**Fig. 11**) reported that in appendiceal neoplasms that show adenomucinosis (DPAM) histology, PCI is an important prognostic indicator and PCI less than 20 has a prognosis of

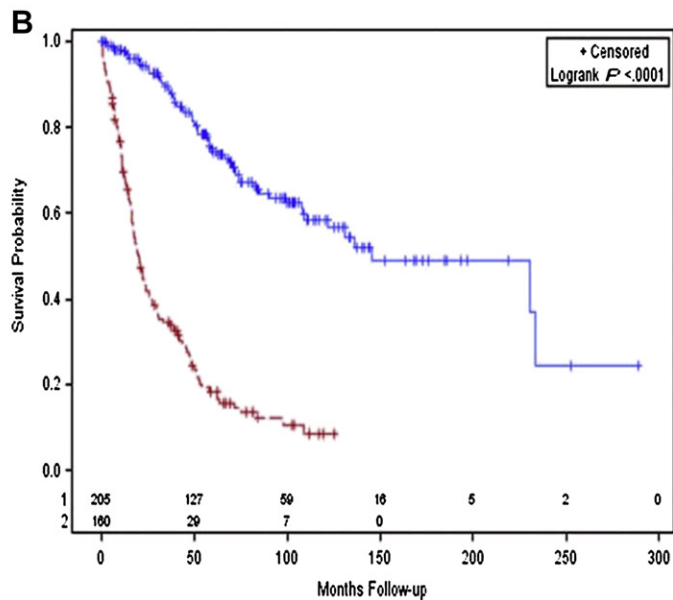
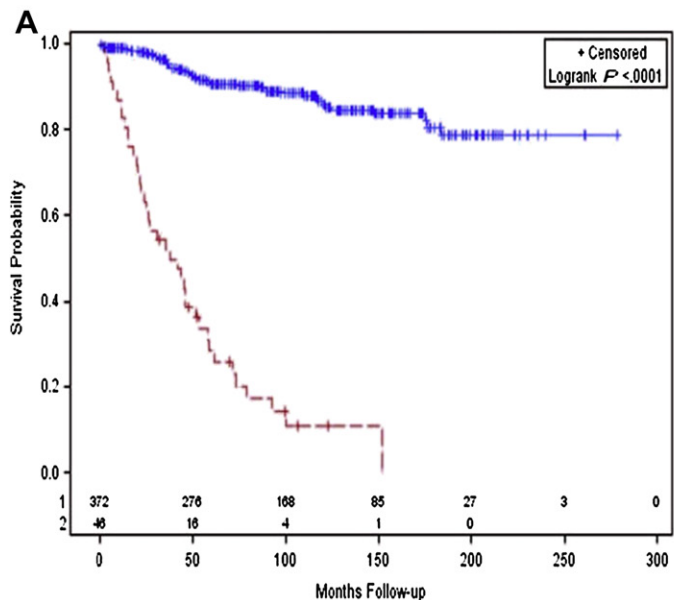


Fig. 9. Survival of patients with mucinous appendiceal neoplasms by CC score. (A) Shows adenomucinosis patients; the blue top line (N = 372) indicates patients with complete cytoreduction, and the red bottom line (N = 46) indicates incomplete cytoreduction. (B) The impact of complete versus incomplete cytoreduction for mucinous carcinoma patients. The blue top line indicates complete cytoreduction (N = 205), and the red bottom line indicates incomplete cytoreduction (N = 160). (Data from Sugarbaker PH. Epithelial appendiceal neoplasms. *Cancer J* 2009;15(3):225–35.)

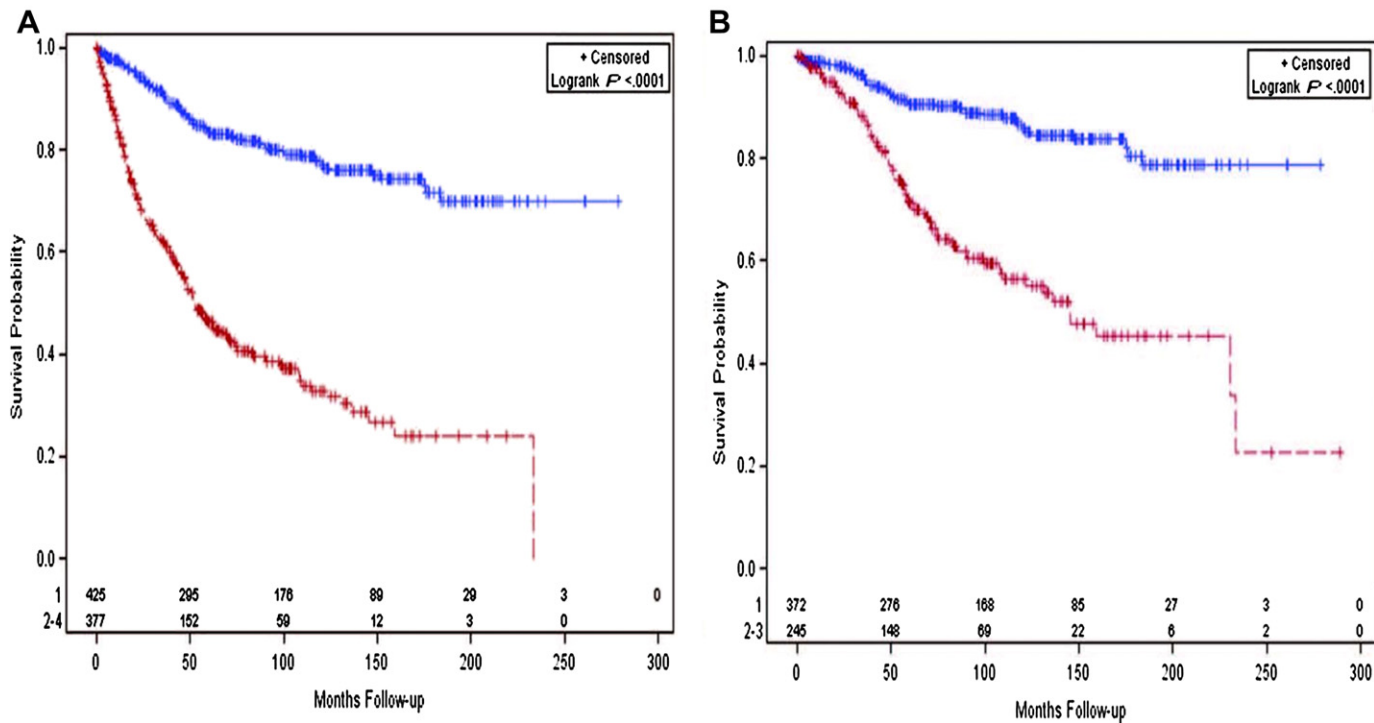


Fig. 10. Survival of patients with mucinous appendiceal neoplasms by histopathology. (A) The blue top line (N = 425) indicates patients with adenomucinoses. The red bottom line (N = 377) indicates patients with mucinous adenocarcinoma and includes patients with intermediate type histology. (B) Limited to patients with a complete cytoreduction. There were 372 adenomucinoses patients (*blue top line*) and 245 patients (*red bottom line*) with mucinous adenocarcinoma. (Data from Sugarbaker PH. Epithelial appendiceal neoplasms. *Cancer J* 2009;15(3):225–35.)

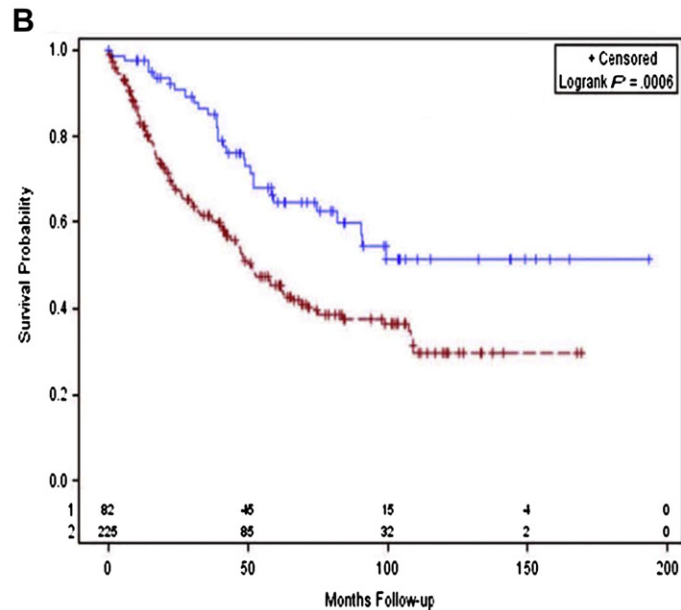
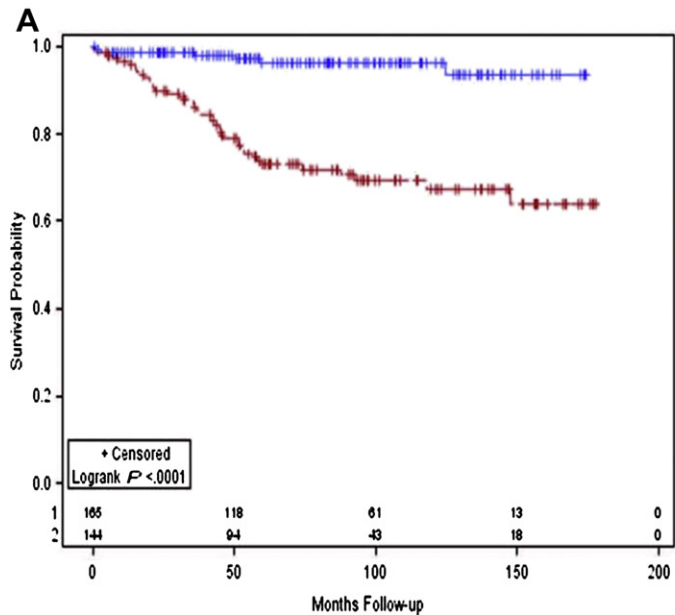


Fig. 11. Survival by PCI for mucinous appendiceal neoplasms. (A) Adenomucinous patients with PCI 1 to 20 (*blue top line*) (N = 165) versus 21 to 39 (*red bottom line*) (N = 144). (B) Mucinous carcinoma patients with PCI 1–20 (*blue top line*) (N = 82) versus 21–39 (*red bottom line*) (N = 225).

94% at 20 years. In patients who have histologically an invasive component, the PCI continues to show statistical difference on survival.¹⁸

Prior Surgical Score

Prior surgical score (PSS) quantitates the extent of surgery performed before the definitive CRS and HIPEC. The previous PCI diagram is used with the exclusion of sites 9 through 12.

PSS = 0, indicates that only a biopsy was performed

PSS = 1, one region with prior surgery

PSS = 2, indicates 2 to 5 regions previously dissected

PSS = 3, indicates more than 5 regions were dissected

PSS of 0 to 2 versus PSS 3 has been shown to have a statistically significant impact on survival in patients with DPAM, with improved survival with lower PSS (**Fig. 12**).¹⁸ PSS does not correlate with significant survival advantage in PMCA patients.¹⁸ The importance of PSS is that multiple and extent of previous surgeries make CRS more difficult and more extensive with prolonged operative time. This translates to higher number of patients having an incomplete CRS.

Lymph Node Involvement

In a study by Gonzalez-Moreno and colleagues,³⁸ lymph node metastases were shown not to affect survival after CRS and HIPEC in patients with appendiceal cancer. In a more recent publication, the same group reported minimal significance of lymph node metastases on overall survival.¹⁸ Lymph node involvement is rarely found in adenomucinosis.

Halabi and colleagues¹⁹ showed, in 77 patients who underwent CRS/HIPEC for PMCA, a 5-year survival status for lymph node-positive versus lymph node-negative of 21% and 73%, respectively ($P < .001$) (**Fig. 13**). All patients had complete cytoreduction. Their data also indicated that patient selection for CRS/HIPEC should take into consideration lymph node status, but it should not be a contraindication if preoperative evaluation revealed a high likelihood of complete cytoreduction.

SYSTEMIC CHEMOTHERAPY IN APPENDICEAL TUMORS

Systemic chemotherapy may have a role in the management of these tumors in 4 different settings:

1. Preoperative (neoadjuvant)
2. Postoperative (adjuvant)
3. Postoperative after suboptimal cytoreduction with residual bulky disease
4. Palliative in unresectable or progressive and metastatic disease

Unfortunately, the role of systemic chemotherapy has not been clarified or defined in any of the clinical settings listed. One main reason is the lack of prospective, randomized studies. Because this is a rare malignancy, a majority of data are from single-institution retrospective reviews. Another reason is the diversity of histologies and the lack of a clear consensus in reporting and describing them. In addition, because the appendix has been considered part of the colon, appendiceal tumors have historically been treated with regimens similar to colorectal adenocarcinomas, although their natural history, biology, and outcomes are different.³⁶

One of the often-quoted retrospective analyses described 34 patients with pseudomyxoma peritonei, diagnosed and treated at Memorial Sloan-Kettering Cancer Center

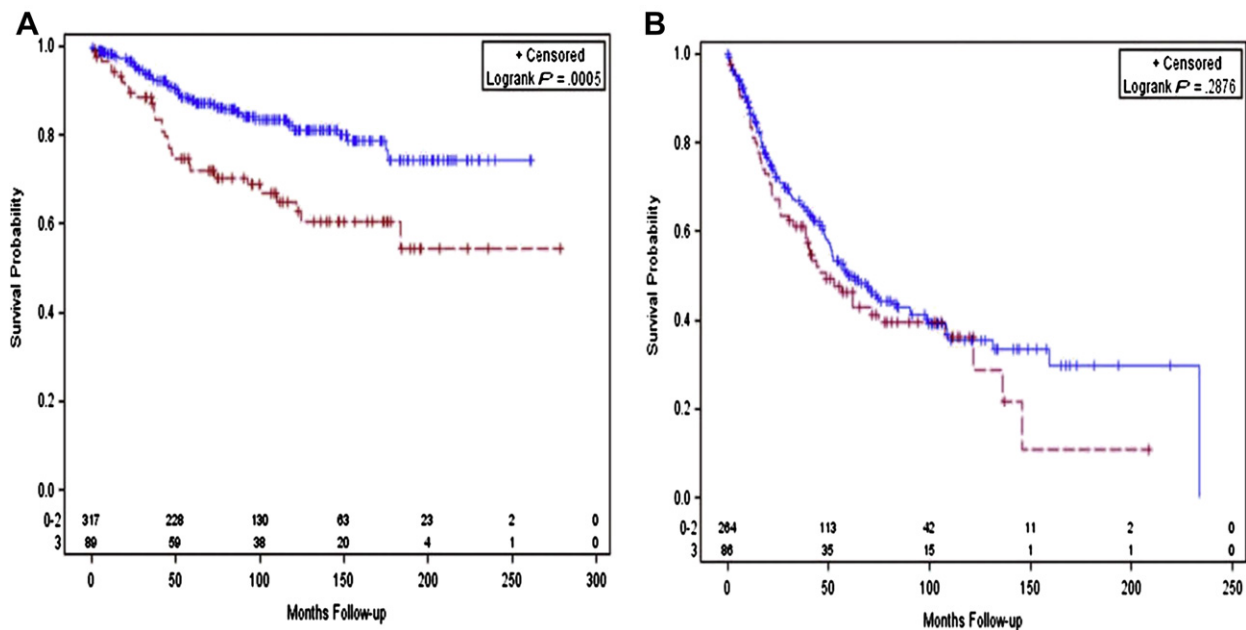


Fig. 12. (A) Survival of patients with mucinous appendiceal neoplasms by PSS. (A) Survival in patients with adenomucinosi of PSS 0 to 2 (*blue top line*) (N = 317) versus PSS of 3 (*red bottom line*) (N = 89). (B) PSS does not have a significant impact on survival of mucinous peritoneal carcinomatosis patients. PSS 0 to 2 (*blue top line*) (N = 264) versus PSS of 3 (*red bottom line*) (N = 86).

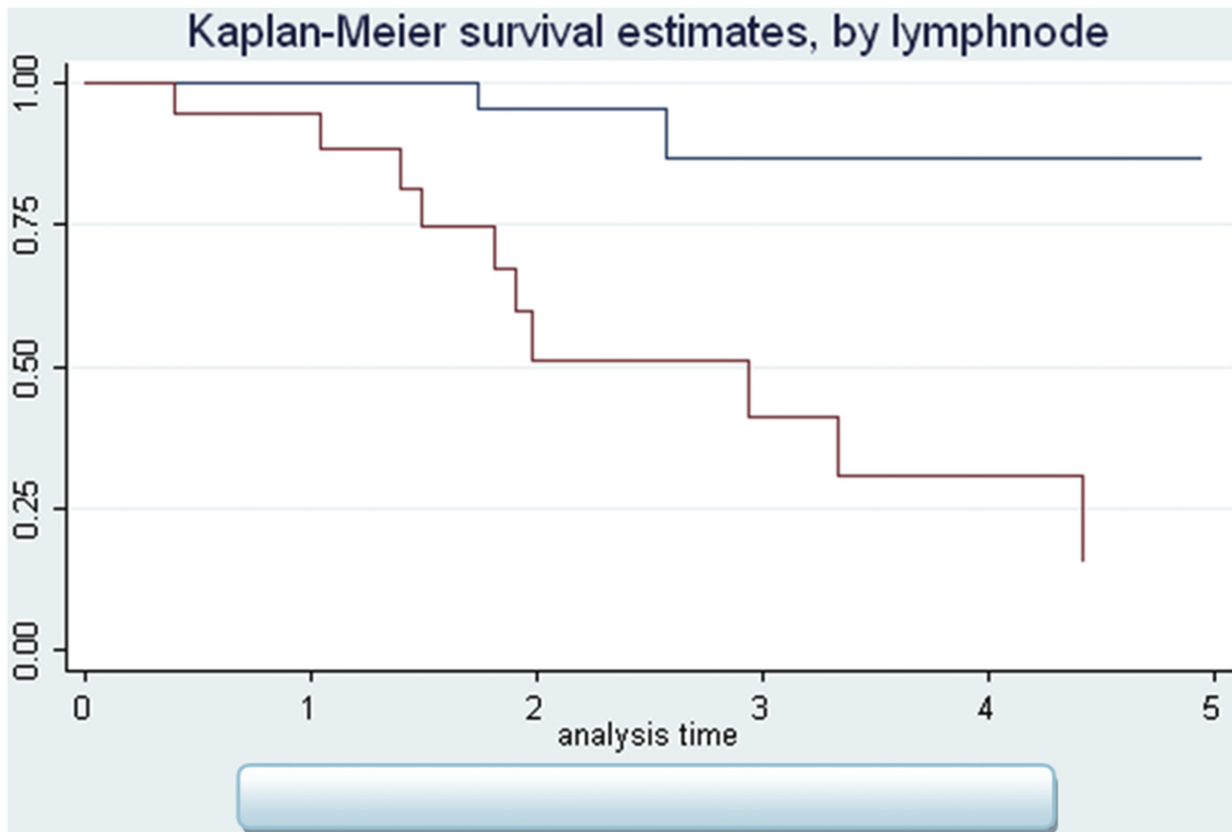


Fig. 13. OS with complete cytoreduction by lymph node status in years (lymph node negative—top line: 76%, lymph node positive—bottom line: 21%).

from 1952 to 1989. Of these, only 17 were of appendiceal origin and only 6 of them received IV chemotherapy with various agents, including 5-fluorouracil (5-FU). This analysis concluded that long-term survival could be obtained by cytoreduction alone, even if gross disease were present at the end of the procedure. No significant difference in survival was noted and chemotherapy should be administered only when there is clinical tumor recurrence.³⁹ Gough and colleagues⁴⁰ reported on 56 patients with pseudomyxoma peritonei treated at the Mayo Clinic between 1957 and 1983. Archival pathology was available in 37 patients and only 20 had appendiceal carcinoma. A majority of tumors were classified as adenocarcinomas grade 1. Adjuvant systemic chemotherapy with agents, such as 5-FU, cyclophosphamide, and doxorubicin, was administered in 27% of the patients after the initial surgery and in 53% after disease recurrence. A univariate analysis indicated that postoperative systemic chemotherapy was associated with shorter survival time. In a more recent study, the Milan group noticed that preoperative systemic chemotherapy had an adverse prognostic value in their series of 104 patients with pseudomyxoma peritonei.⁴¹ Although most of those tumors were of appendiceal origin, 78 were DPAM and only 26 were characterized as PMCA. Twenty-six patients received preoperative chemotherapy and 23 of them were able to undergo cytoreduction and HIPEC. A breakdown of the chemotherapy group by histology and the agents used were not reported. Preoperative chemotherapy seemed to correlate with reduced both overall survival and progression-free survival (PFS). The investigators noted, however, that a selection bias could have occurred and the patients treated with chemotherapy could be the ones with aggressive disease.

Whether the particularly aggressive histologies may benefit more from preoperative or postoperative chemotherapy remains an open question. The signet ring cell carcinoma variance is typically a poorly differentiated tumor with a worse survival compared with mucinous adenocarcinoma.²³ Chua and colleagues²⁴ reported on 33 patients with signet ring cell carcinoma of colorectal (15 cases) or appendiceal (18 cases) origin. In the appendiceal group, 11 patients received systemic chemotherapy with FOLFOX (5-FU, oxaliplatin, and leucovorin) with or without bevacizumab before CRS. The median survival was 27 months in the combined chemotherapy with CRS/HIPEC group and 15 months for the chemotherapy-only patients. In a recent retrospective study of a larger series (142 patients) of appendiceal adenocarcinoma, either poorly differentiated (114 cases) or with signet ring histology (28 cases), Lieu and colleagues²⁵ evaluated the role of systemic chemotherapy with modern agents; 78 patients with metastatic disease received upfront systemic chemotherapy. The overall radiographic response rate was 44% and an additional 42% of the patients treated had stable disease. The median PFS was 6.9 months and the median overall survival (OS) 1.7 years. The majority of the patients received oxaliplatin combined with 5-FU or capecitabine and 17% of patients received irinotecan; 26 patients also received bevacizumab. There was no statistically significant difference between the regimens in response rate, PFS, or OS. Forty-five patients received second-line chemotherapy but only 13% responded. The PFS in that cohort was only 2.3 months. In multivariate analysis, a response to chemotherapy was associated with improved PFS but not OS. Only complete cytoreduction improved OS.

When the investigators from the University of Texas MD Anderson Cancer Center evaluated the role of systemic chemotherapy in unresectable appendiceal neoplasms with less aggressive histology, a potential benefit was more clear.²⁶ Fifty-four patients received at least 2 cycles of chemotherapy. The overall response rate, including stable disease, was 56%. Sixteen patients underwent CRS postchemotherapy. This was a cohort of patients with better prognosis. Only 30% of tumors had signet ring cell

histology and 45% were well differentiated. The median PFS was 7.6 months and the OS was 56 months. The agents used were mainly 5-FU and capecitabine combined with platinum but also irinotecan, bevacizumab, and cetuximab. One-third of the patients received 5-FU or capecitabine alone. Cetuximab and other epidermal growth factor receptor inhibitors are used similarly to colorectal cancer although their association with the KRAS and BRAF mutations has not been properly investigated or defined in appendiceal tumors. Therefore, even in the absence of prospective data, it seems that systemic chemotherapy with modern agents may have a role in histologically aggressive as well as the primarily unresectable appendiceal tumors.

Sugarbaker and colleagues²⁷ conducted a prospective study evaluating the role of neoadjuvant chemotherapy with FOLFOX in PMCA. Between 2005 and 2009 they treated 34 consecutive patients. Although 65% of the patients on chemotherapy had stable disease by CT evaluation, intraoperative findings demonstrated disease progression in 50% of the patients, and 29% of patients had a combined partial and complete response by histopathology. That indicates the limitations of imaging studies in the preoperative setting. In a retrospective analysis of 77 patients with PMCA who underwent cytoreduction in the authors' institution,²⁸ preoperative chemotherapy correlated with worse OS and relapse-free survival (RFS). Most patients received an oxaliplatin-based or irinotecan-based regimen; the subgroup of patients who received additional bevacizumab seemed to have better outcomes, but the difference was not statistically significant. There was a concern that preoperative chemotherapy might delay the surgery and, therefore, hinder the attempt for complete and timely cytoreduction.

The role of chemotherapy in the adjuvant setting after complete CRS and HIPEC is even less clear. There is a lack of prospective analysis and a majority of data are from small patient cohorts and case reports.²⁹ Many patients with tumors of aggressive histology are treated empirically similar to adjuvant therapy for colorectal cancer, despite that the most common pattern of recurrence after complete cytoreduction is locoregional disease and subsequent surgical resections may improve survival. Traditionally, most patients with suboptimal CRS and good performance status receive postoperative systemic chemotherapy for palliation or with the goal to facilitate a second cytoreduction if there is a significant response.

There is a need to determine if there is any contribution of systemic chemotherapy in the management of appendiceal tumors, a need to identify subtypes with a more aggressive biologic behavior that may benefit from chemotherapy, and a need to prospectively explore various chemotherapy agents instead of just applying the same regimens as for colorectal cancer. This effort requires prospective phase II and III trials, which are difficult to conduct because of the rarity of the disease. The significance of various molecular targets, as in colorectal adenocarcinoma, lung, and breast cancer, should be investigated.

Although the histology (ie, poorly differentiated PMCA or signet ring cells) has prognostic value, the complex behavior of these tumors may be better understood by molecular profiling. Leptin; the mucin core proteins, MUC2 and MUC5ACI; and the mammalian target of rapamycin (mTOR) are more frequently expressed in mucinous adenocarcinomas compared with adenomas.³⁰ The mTOR-immunopositive group of patients had decreased disease-free survival (DFS), an outcome that could be potentially modified by the use of the mTOR inhibitors class of agents. These findings were supported by an earlier observation of high expression but variable distribution of MUC2 in DPAM and PMCA. The MUC2 expression correlated with high density of enteric bacteria and, specifically, *H pylori*.³¹ A previously published study by Yajima and colleagues³² reported higher levels of p53 protein expression in mucinous

carcinomas compared with mucinous adenomas, although there was no difference in expression between adenomas and carcinomas in the nonmucinous tumors. Logan-Collins and colleagues³³ explored the vascular endothelial growth factor (VEGF) expression in mucinous adenocarcinomas of the appendix after prior cytoreduction. There was increased expression in 94% of their specimens. Higher VEGF expression was associated with worse OS. This retrospective analysis indicates there may be a role for angiogenesis in the growth of peritoneal lesions. It needs to be validated by prospective clinical data. Yoon and colleagues⁴² showed that 9 proteins were more frequently altered in the adenocarcinoma versus adenoma group: cyclin D1, β -catenin, Ki-67, nuclear factor κ B, VEGF, E-cadherin, p53, MUC2, and MUC5AC. Furthermore, the number of altered protein markers, p53 overexpression, nuclear factor κ B positivity, and β -catenin loss correlated with adverse clinical outcomes.

The notion that appendiceal cancer is biologically similar and, therefore, should be treated with chemotherapy identical to colon was challenged in a recent study by Levine and colleagues.³⁶ A prospectively maintained tissue bank of peritoneal metastases from appendiceal and colorectal cancers after CRS and HIPEC and 3 years of follow-up was used. The majority of appendiceal cancers were low histologic grade. Global gene expression analysis and unsupervised hierarchical clustering were performed. Three main clusters were produced: two clusters consisted of predominantly appendiceal samples and a third consisting of colorectal samples. The results of survival analysis were intriguing: the colorectal samples had the worst prognosis, with no survival at 5 years. Despite their low histologic grade, however, the appendiceal cancer clusters had statistically different survival curves compared with each other and they were labeled low risk and high risk. The MUC2, MUC5AC, and trefoil factors 1 and 2 genes correlated with worse prognosis. Additional genes, such as SRC and TGF- β , were shown differentially regulated in the high-risk group. The study demonstrated a distinct molecular profile and, therefore, different biology between colorectal and appendiceal cancer. The results may suggest that targeted agents, such as Src inhibitors (the investigators discuss dasatinib) or vaccine therapy, could be considered for clinical trials.

In summary, despite more than 5 decades of using systemic chemotherapy in appendiceal cancer, understanding of its role is still limited. It seems that chemotherapy may be helpful in advanced, high-grade disease, particularly when complete cytoreduction is not feasible. This information, however, is mainly derived from retrospective single-institution data and general medical oncology practice is based on the erroneous notion that appendiceal and colorectal cancers are similar and they can therefore, be treated with identical chemotherapy regimens.

MORTALITY AND MORBIDITY WITH PERITONECTOMY AND HIPEC

The postoperative morbidity rates reported in the literature range from 14% to 70%.⁴³⁻⁴⁹ Patients with complications are identified clinically with fatigue, increasing inflammatory parameters, dehydration, and occasionally pancytopenia that may aggravate the situation. Complications that occur may depend on⁵⁰⁻⁵⁴

- Metachronous peritoneal carcinomatosis ($P = .009$)
- PCI >13 ($P = .012$)
- Five or more affected regions ($P = .04$)
- Incomplete initial cytoreduction ($P = .035$)
- Blood transfusion requirements due to intraoperative blood loss ($P = .28$)
- Three or more anastomosis ($P = .018$)

Table 2

Compilation of recent series from multiple institutions across the world of peritoneal carcinomatosis of appendiceal origin treated with CRS and HIPEC

Author/Center	Year	N	Histology	Drugs	Temp (°)	CC-0	DFS	OS	Mortality
Stewart et al ⁵⁵ (Wake Forest)	2006	110	DPAM: (50%) Intermediate: (16%) PMCA: 27% High-grade nonmucinous: 7%	MMC	42	R0 (n = 31) R1 (n = 17)		1 y: 79.9% 3 y: 59% 5 y: 53.4%	4% 30-d Mortality
Sardi et al ³⁷ (Mercy- Baltimore)	2009	56	DPAM: 39.2% PMCA: 60.7%	MMC	42			DPAM (3 y): 80% PMCA (3 y): 52%	0% (Postoperative)
Vaira et al ⁵⁶ (Italy)	2009	60	Adenocarcinoma appendix: 71.6% DPAM: 28.3%	MMC + Cisplatin	41.5	—	5 y: 80% 10 y: 70%	5 y: 94% 10 y: 84.6%	0% (Postoperative)
Sideris et al ⁵⁷ (Montreal)	2009	37	PMCA (29%) DPAM: grade 0: 21% grade 1: 50%	MMC (HIPEC) 5-FU (EPIC)	42–43	64%	—	5 y: 59% (HIPEC) 5 y: 58% (EPIC)	0% (Postoperative)
Järvinen et al ⁵⁸ (Finland)	2010	33	Pseudomyxoma peritonei appendix	—	—	—	—	5 y: 67% 10 y: 31%	2.7% (30-d Mortality)
Elias et al ⁵⁹ (France)	2010	41	Adenocarcinoma appendix	MMC (HIPEC) MMC + 5-FU (EPIC)	40–43	71.5%	89 Mo	3 y: 63.2% 5 y: 63.2%	4.8% (Postoperative)
Ko et al ⁶⁰ (Korea)	2010	55	Adenocarcinoma appendix	—	—	—	3 y: 66.4% 5 y: 53.3%	3 y: 72.2% 5 y: 64%	—
Youssef et al ⁶¹ (UK)	2011	456	Pseudomyxoma peritonei appendix	MMC	42	66%	9.2 y (mean)	5 y: 69% 10 y: 74%	1.65% In-hospital mortality
Chua et al ³⁴ (Australia)	2011	46	Mucinous and nonmucinous adenocarcinoma appendix	MMC	42	72%	20.5 Mo	3 y: 59% 5 y: 45% 7 y: 34%	4%
Austin et al ⁶² (UPMC- Pittsburgh)	2012	282	PMCA (75%) DPAM (25.2%)	MMC	42	49.3	—	3 y: 67.4 5 y: 52.7	1.1% (60-d Mortality)
El Halabi et al ³⁵ (Mercy-Baltimore)	2012	77	PMCA	MMC	42	PCI >20 65% PCI <20 96%		1 y: 88% 3 y: 56% 5 y: 40%	0%

Abbreviations: EPIC, early postoperative intraperitoneal chemotherapy; MMC, mitomycin C; N, number of patients; Temp, temperature in degrees centigrade.

Reported mortality rates are in the range of 0% to 20% in the world literature and 0% to 8% at active peritoneal carcinomatosis centers. A major impact in reducing morbidity and mortality is the learning curve of CRS with HIPEC, suggesting that surgeons should first visit established peritoneal surface malignancy centers before performing these operative procedures.³² The morbidity and mortality rates of CRS and HIPEC are similar to other major gastrointestinal surgeries but these can be further reduced in high-volume peritoneal surface malignancy centers.

Table 2^{34,35,37,55–62} shows a compilation of recent series from multiple institutions across the world of peritoneal carcinomatosis of appendiceal origin treated with CRS and HIPEC. As shown, the mortality rates from CRS/HIPEC ranges in these series from 0% to 4.8%.

QUALITY OF LIFE AFTER CRS AND HIPEC

Despite the reported initial impairment QOL, several studies show an improvement of QOL after CRS and HIPEC in long-term survivors.^{63–67} Schmidt and colleagues⁶³ evaluated QOL after CRS and HIPEC in 67 patients with peritoneal carcinomatosis using the EORTC QLQ-C30 questionnaire. The mean score for global health status of long-term survivors was significantly decreased compared with the control population (62.6 vs 73.3) showing particularly an impairment of role and social functioning.

McQuellon and colleagues⁶⁴ reported that patients initially have a decrease of physical, functional, and well-being scores, but this does increase relative to baseline levels during follow-up at 3, 6, and 12 months. One year after surgery, 74% of the patients resumed greater than 50% of their normal activities. They also concluded that significant number of patients show depressive symptoms at the time of surgery (32%) as well as 1 year after surgery (24%).⁶⁷

Tuttle and colleagues⁶⁶ showed a return of QOL measurements to baseline 4 months after surgery in a prospective analysis of 35 patients. Eight and 12 months after CRS and HIPEC, QOL was significantly improved. In conclusion, the existing studies show that CRS and HIPEC can be performed with acceptable postoperative QOL and even may improve QOL in a selected group of long-term survivors.

SUMMARY

Appendiceal tumors historically were considered rare tumors but their incidence is rising. Appendiceal mucinous neoplasms represent a homogeneous group of neoplasms and, if confined to the appendiceal mucosa, are cured by appendectomy, whereas any proliferation of neoplastic epithelium beyond the mucosa or rupture of the appendix places patients at risk for peritoneal dissemination. There is significant interobserver variability when classifying these tumors based on Ronnett's criteria.¹² In addition, there is clinical variability in the behavior of tumors within this classification system; a small percentage of patients with DPAM demonstrate a more aggressive clinical picture, whereas a variable spectrum of biologic behavior may be seen in patients with PMCA. Historically, these tumors were treated with nonaggressive, serial debulking procedures, mainly for symptom management, with selective use of intraperitoneal chemotherapy. Tumor recurrence was high and cure was uncommon. Sugarbaker¹⁸ introduced the concept of radical CRS to remove all macroscopic tumor deposits, followed by perioperative intraperitoneal chemotherapy to treat residual microscopic disease. The peritoneal-based nature of this appendicular malignancy makes it an ideal candidate for aggressive locoregional therapies. Decisions regarding clinical management require clear communication among treating physicians, so

adoption of a uniform reporting system for appendiceal mucinous neoplasms with peritoneal metastases by the World Health Organization and American Joint Committee on Cancer represents a major advancement in the field.

Improved patient survival has been demonstrated, with the use of CRS and HIPEC with reduced tumor recurrence and less need for potentially morbid reoperative interventions. Current evidence demonstrates that peritoneal carcinomatosis from mucinous appendiceal neoplasms has a median survival of 51 to 156 months, a 10 year overall survival upto 70%, while maintaining overall morbidity of 20 - 50% and mortality of 1-10%.⁶² Meaningful long-term survival can be achieved in patients with PMCA even with extensive peritoneal disease. Extensive multivisceral resections can be performed even in the setting of recurrent disease, with low major morbidity at experienced centers. Once controlled for complete cytoreduction, a PCI greater than 20 that suggests extensive disease should not be an exclusion criterion for surgery even in high-grade disease. Instead, complete cytoreduction of extensive disease is a more important factor, and all efforts should be made at surgery to achieve it.³⁵ This requires longer operative time and advanced surgical expertise in treating such disease. Delaying CRS/HIPEC may complicate the surgical approach and lower the possibility of complete cytoreduction.³⁵ The number of lymph nodes to be harvested in appendiceal cancer has not been standardized. Multi-institutional efforts should be made to classify further patients with positive lymph node into subcategories based on the ratio or number of positive lymph nodes.

Despite more than 5 decades of using systemic chemotherapy in appendiceal cancer, understanding of its role is limited. There is an urgent need to design and conduct phase II prospective trials that use and further explore available preclinical data and attempt to integrate cytotoxics with targeted agents. Those trials may need to be collaborative and multicenter because of the rarity of the disease. In the meantime, because a majority of patients are treated empirically, there is a risk of unnecessary toxicity and the benefit to survival outcomes is uncertain. Questions will arise about the effectiveness of short duration precytoreduction chemotherapy for patients with PMCA and lymph node involvement.

Due to the complexity in decision making, these patients are better managed through a multidisciplinary approach, preferably by a team with expertise in peritoneal surface malignancy. In conclusion, appropriate patient selection, complete cytoreduction, and low morbidity are modifiable factors in this disseminated malignancy, and aggressive management by experienced surgeons can lead to long-term survival.

REFERENCES

1. Connor SJ, Hanna GB, Frizelle FA. Appendiceal tumors: retrospective clinicopathologic analysis of appendiceal tumors from 7,970 appendectomies. *Dis Colon Rectum* 1998;41(1):75.
2. McCusker ME, Coté TR, Clegg LX, et al. Primary malignant neoplasms of the appendix: a population-based study from the surveillance, epidemiology and end-results program, 1973-1998. *Cancer* 2002;94(12):3307.
3. Elting AW. Primary carcinoma of the vermiform appendix, with a report of three cases. *Ann Surg* 1903;37(4):549-74.
4. AJCC cancer staging manual. 7th edition. American Joint Committee on Cancer, 2010, Springer.
5. Prystowsky JB, Pugh CM, Nagle AP. Current problems in surgery: appendicitis. *Curr Probl Surg* 2005;42:688-742.

6. Gustafsson B, Siddique L, Chan A, et al. Uncommon cancers of the small intestine, appendix and colon: an analysis of SEER 1973-2004, and current diagnosis and therapy. *Int J Oncol* 2008;33:1121–31.
7. Misdraji J. Appendiceal mucinous neoplasms: controversial issues. *Arch Pathol Lab Med* 2010;134(6):864–70.
8. Higa E, Rosai J, Pizzimbono CA, et al. Mucosal hyperplasia, mucinous cystadenoma, and mucinous cystadenocarcinoma of the appendix. A re-evaluation of appendiceal “mucocele”. *Cancer* 1973;32(6):1525–41.
9. Carr NJ, McCarthy WF, Sobin LH. Epithelial noncarcinoid tumors and tumor-like lesions of the appendix. A clinicopathologic study of 184 patients with a multivariate analysis of prognostic factors. *Cancer* 1995;75(3):757–68.
10. Misdraji J, Yantiss RK, Graeme-Cook FM, et al. Appendiceal mucinous neoplasms: a clinicopathologic analysis of 107 cases. *Am J Surg Pathol* 2003;27(8):1089–103.
11. Pai RK, Longacre TA. Appendiceal mucinous tumors and pseudomyxoma peritonei: histologic features, diagnostic problems, and proposed classification. *Adv Anat Pathol* 2005;12(6):291–311.
12. Ronnett BM, Zahn CM, Kurman RJ. Disseminated peritoneal adenomucinosis and peritoneal mucinous carcinomatosis. A clinicopathologic analysis of 109 cases with emphasis on distinguishing pathologic features, site of origin, prognosis, and relationship to “pseudomyxoma peritonei”. *Am J Surg Pathol* 1995;19(12):1390–408.
13. Deschamps L, Couvelard A. Endocrine tumors of the appendix: a pathologic review. *Arch Pathol Lab Med* 2010;134(6):871–5.
14. Rindi G, Klöppel G, Couvelard A, et al. TNM staging of midgut and hindgut (neuro) endocrine tumors: a consensus proposal including a grading system. *Virchows Arch* 2007;451(4):757–62.
15. Subbuswamy SG, Gibbs NM, Ross CF, et al. Goblet cell carcinoid of the appendix. *Cancer* 1974;34(2):338–44.
16. Roy P, Chetty R. Goblet cell carcinoid tumors of the appendix: an overview. *World J Gastrointest Oncol* 2010;2(6):251–8.
17. Tang LH. Epithelial neoplasms of the appendix. *Arch Pathol Lab Med* 2010;134(11):1612–20.
18. Sugarbaker PH. Epithelial appendiceal neoplasms. *Cancer J* 2009;15(3):225–35.
19. Halabi HE, Gushchin V, Francis J, et al. Prognostic significance of lymph node metastases in patients with high-grade appendiceal cancer. *Ann Surg Oncol* 2012;19(1):122–5.
20. Ross A, Sardi A, Nieroda C, et al. Clinical utility of elevated tumor markers in patients with disseminated appendiceal malignancies treated by cytoreductive surgery and HIPEC. *Eur J Surg Oncol* 2010;36(8):772–6.
21. Sugarbaker PH. Technical handbook for the integration of cytoreductive surgery and perioperative intraperitoneal chemotherapy into the surgical management of gastrointestinal and gynecologic malignancy. 4th edition. Grand Rapids (MI): Ludann company; 2005.
22. Gonzalez –Moreno S, Gonzalez Bayon LA, Ortega Perez G. Hyperthermic intraperitoneal chemotherapy: rationale and technique. *World J Gastrointest Oncol* 2010;2(2):68–75.
23. Kang H, O’Connell JB, Maggard MA, et al. A 10-year outcomes evaluation of mucinous and signet-ring cell carcinoma of the colon and rectum. *Dis Colon Rectum* 2005;48:1161–8.
24. Chua TC, Pelz JO, Kerscher A, et al. Critical analysis of 33 patients with peritoneal carcinomatosis secondary to colorectal and appendiceal signet ring cell carcinoma. *Ann Surg Oncol* 2009;16:2765–70.

25. Lieu CH, Lambert LA, Wolff RA, et al. Systemic chemotherapy and surgical cytoreduction in poorly differentiated and signet ring cell adenocarcinomas of the appendix. *Ann Oncol* 2012;23:652–8.
26. Shapiro JF, Chase JL, Wolff RA, et al. Modern systemic chemotherapy in surgically unresectable neoplasms of appendiceal origin. *Cancer* 2010;116:316–22.
27. Sugarbaker PH, Bijelic C, Chang D, et al. Neoadjuvant FOLFOX chemotherapy in 34 consecutive patients with mucinous peritoneal carcinomatosis of appendiceal origin. *J Surg Oncol* 2010;102(6):576–81.
28. El Halabi HM, Ledakis P, Gushchin V, et al. The role of cytoreductive surgery in patients with carcinomatosis from high-grade appendix cancer in the era of modern systemic chemotherapy. *J Clin Oncol* 2011;29(Suppl):4080.
29. Chen CF, Huang CJ, Kang WY, et al. Experience with adjuvant chemotherapy for pseudomyxoma peritonei secondary to mucinous adenocarcinoma of the appendix with oxaliplatin/fluorouracil/leucovorin (FOLFOX4). *World J Surg Oncol* 2008;11(6):118.
30. Chang MS, Byeon SJ, Yoon SO, et al. Leptin, MUC2 and mTOR in appendiceal mucinous neoplasms. *Pathobiology* 2012;79(1):45–53.
31. Semino-Mora C, McAvoy T, Nieroda C, et al. Pseudomyxoma peritonei: is disease progression related to microbial agents? A study of bacteria, MUC2 and MUC5AC expression in disseminated peritoneal adenomucinosis and peritoneal mucinous carcinomatosis. *Ann Surg Oncol* 2008;15(5):1414–23.
32. Yajima N, Wada R, Yamagishi S, et al. Immunohistochemical expressions of cytokeratins, mucin core proteins, p53, and neuroendocrine cell markers in epithelial neoplasm of appendix. *Hum Pathol* 2005;36(11):1217–25.
33. Logan-Collins JM, Lowy AM, Robinson-Smith TM, et al. VEGF expression predicts survival in patients with peritoneal surface metastases from mucinous adenocarcinoma of the appendix and colon. *Ann Surg Oncol* 2007;15(3):738–44.
34. Chua TC, Al-Alem I, Saxena A, et al. Surgical cytoreduction and survival in appendiceal cancer peritoneal carcinomatosis: an evaluation of 46 consecutive patients. *Ann Surg Oncol* 2011;18:1540–6.
35. El Halabi H, Gushchin V, Francis J, et al. The role of cytoreductive surgery and heated intraperitoneal chemotherapy in patients with high-grade appendiceal carcinoma and extensive peritoneal carcinomatosis. *Ann Surg Oncol* 2012;19:110–4.
36. Levine EA, Blazer DG 3rd, Kim MK. Gene expression profiling of peritoneal metastases from appendiceal and colon cancer demonstrates unique biologic signatures and predicts patient outcomes. *J Am Coll Surg* 2012;214(4):599–606.
37. Omohwo C, Nieroda CA, Gushchin V, et al. Complete cytoreduction offers long term survival in patients with peritoneal carcinomatosis from appendiceal tumors of unfavourable histology. *J Am Coll Surg* 2009;209(3):308–12.
38. Gonzalez-Moreno S, Brun E, Sugarbaker PH. Lymph node metastases in epithelial malignancies of the appendix with peritoneal dissemination does not reduce survival in patients treated by cytoreductive surgery and perioperative intraoperative chemotherapy. *Ann Surg Oncol* 2005;12(1):72–80.
39. Smith JW, Kemeny N, Caldwell C, et al. Pseudomyxoma peritonei of appendiceal origin. The Memorial Sloan-Kettering Cancer Center experience. *Cancer* 1992;70:396–401.
40. Gough DB, Donohue JH, Schutt AJ, et al. Pseudomyxoma peritonei. Long-term patient survival with an aggressive regional approach. *Ann Surg* 1994;219:112–9.

41. Baratti D, Kusamura S, Nonaka D, et al. Pseudomyxoma peritonei: clinical pathological and biological prognostic factors in patients treated with cytoreductive surgery and hyperthermic intraperitoneal chemotherapy (HIPEC). *Ann Surg Oncol* 2008;15(2):526–34.
42. Yoon SO, Kim B, Lee HS, et al. Differential protein immunoexpression profiles in appendiceal mucinous neoplasms: a special reference to classification and predictive factors. *Mod Pathol* 2009;22:1102–12.
43. Rohani P, Scotti SD, Shen P. Use of FDG-PET imaging for patients with disseminated cancer of the appendix. *Am Surg* 2010;76(12):1338–44.
44. Verwaal VJ, van Tinteren H, van Ruth S, et al. Predicting the survival of patients with peritoneal carcinomatosis of colorectal origin treated by aggressive cytoreduction and hyperthermic intraperitoneal chemotherapy. *Br J Surg* 2004;91:739–46.
45. Stephens AD, Alderman R, Chang D, et al. Morbidity and mortality analysis of 200 treatments with cytoreductive surgery and hyperthermic intraoperative intraperitoneal chemotherapy using coliseum technique. *Ann Surg Oncol* 1999;6:790–6.
46. Saxena A, Yan TD, Morris DL, et al. A critical evaluation of risk factors for complications after cytoreductive surgery and perioperative intraperitoneal chemotherapy for colorectal peritoneal carcinomatosis. *World J Surg* 2010;34:70–8.
47. Saxena A, Chua TC, Yan TD, et al. Postoperative pancreatic fistula after cytoreductive surgery and perioperative intraperitoneal chemotherapy: incidence, risk factors, management and clinical sequel. *Ann Surg Oncol* 2010;17(5):1302–10.
48. Kerscher AG, Mallalieu J, Pitroff A, et al. Morbidity and mortality of 109 consecutive cytoreductive procedures with hyperthermic intraperitoneal chemotherapy (HIPEC) performed at a community hospital. *World J Surg* 2010;34:62–9.
49. Glehen O, Osinsky D, Cotte E. Intraperitoneal chemohyperthermia using a closed abdominal procedure and cytoreductive surgery for the treatment of peritoneal carcinomatosis: morbidity and mortality analysis of 216 consecutive procedures. *Ann Surg Oncol* 2003;10(8):863–9.
50. Esquivel J, Vidal-Jove J, Steves MA, et al. Morbidity and mortality of cytoreductive surgery and intraperitoneal chemotherapy. *Surgery* 1993;113(6):631–6.
51. Kusamura S, Younan R, Baratti D, et al. Cytoreductive surgery followed by intraperitoneal hyperthermic perfusion: analysis of morbidity and mortality in 209 peritoneal surface malignancies treated with closed abdomen technique. *Cancer* 2006;106(5):1144–53.
52. Verwaal VJ, van Tinteren H, Ruth SV, et al. Toxicity of cytoreductive surgery and hyperthermic intra-peritoneal chemotherapy. *J Surg Oncol* 2004;85(2):61–7.
53. Franko J, Gusani NJ, Holtzman MP, et al. Multivisceral resection does not affect morbidity and survival after cytoreductive surgery and chemoperfusion for carcinomatosis from colorectal cancer. *Ann Surg Oncol* 2008;15(11):3065–72.
54. Moradi BN, Esquivel J. Learning curve in cytoreductive surgery and hyperthermic intraperitoneal chemotherapy. *J Surg Oncol* 2009;100:293–6.
55. Stewart JH IV, Shen P, Russel GB, et al. Appendiceal neoplasms with peritoneal dissemination: outcomes after cytoreductive surgery and intraperitoneal hyperthermic chemotherapy. *Ann Surg Oncol* 2006;13(5):624–34.
56. Vaira M, Cioppa T, De Marco G, et al. Management of pseudomyxoma peritonei by cytoreduction+HIPEC (hyperthermic intraperitoneal chemotherapy): results analysis of a twelve-year experience. *In Vivo* 2009;23(4):639–44.
57. Sideris L, Mitchell A, Drolet P. Surgical cytoreduction and intraperitoneal chemotherapy for peritoneal carcinomatosis arising from the appendix. *Can J Surg* 2009;52(2):135–41.

58. Järvinen P, Järvinen HJ, Lepistö A, et al. Survival of patients with pseudomyxoma peritonei treated by serial debulking. *Colorectal Dis* 2010;12(9):868–72.
59. Elias D, Glehen O, Pocard M, et al. A comparative study of complete cytoreductive surgery plus intraperitoneal chemotherapy to treat peritoneal dissemination from colon, rectum, small bowel, and nonpseudomyxoma appendix. *Ann Surg* 2010;251(5):896–901.
60. Ko YH, Park SH, Jung CK, et al. Clinical characteristics and prognostic factors for primary appendiceal carcinoma. *Asia Pac J Clin Oncol* 2010;6(1):19–27.
61. Youssef H, Newman C, Chandrakumaran K, et al. Operative findings, early complications, and long-term survival in 456 patients with pseudomyxoma peritonei syndrome of appendiceal origin. *Dis Colon Rectum* 2011;54(3):293–9.
62. Austin F, Mavanur A, Sathaiah M, et al. Aggressive management of peritoneal carcinomatosis from mucinous appendiceal neoplasms. *Ann Surg Oncol* 2012;19(5):1386–93.
63. Schmidt U, Dahlke MH, Klemptner J, et al. Perioperative morbidity and quality of life in long-term survivors following cytoreductive surgery and hyperthermic intraperitoneal chemotherapy. *Eur J Surg Oncol* 2005;31:53–8.
64. McQuellon RP, Loggie BW, Fleming RA, et al. Quality of life after intraperitoneal hyperthermic chemotherapy (IPHC) for peritoneal carcinomatosis. *Eur J Surg Oncol* 2001;27:65–73.
65. McQuellon RP, Loggie BW, Lehman AB, et al. Long-term survivorship and quality of life after cytoreductive surgery plus intraperitoneal hyperthermic chemotherapy for peritoneal carcinomatosis. *Ann Surg Oncol* 2003;10:155–62.
66. Tuttle TM, Zhang Y, Greeno E, et al. Toxicity and quality of life after cytoreductive surgery plus hyperthermic intraperitoneal chemotherapy. *Ann Surg Oncol* 2006;13:1627–32.
67. McQuellon RP, Danhauer SC, Russell GB, et al. Monitoring health outcomes following cytoreductive surgery plus intraperitoneal hyperthermic chemotherapy for peritoneal carcinomatosis. *Ann Surg Oncol* 2007;14:1105–13.